Imaging Iron Oxide Nanoparticles in Animal Models

Leslie L. Muldoon, Ph.D.

Edward A. Neuwelt, M.D.

MR Imaging in Rats

Custom made rat head coil

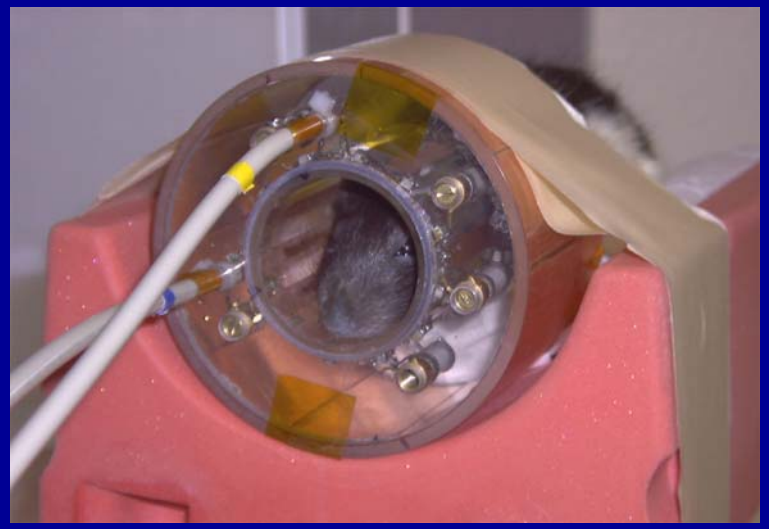

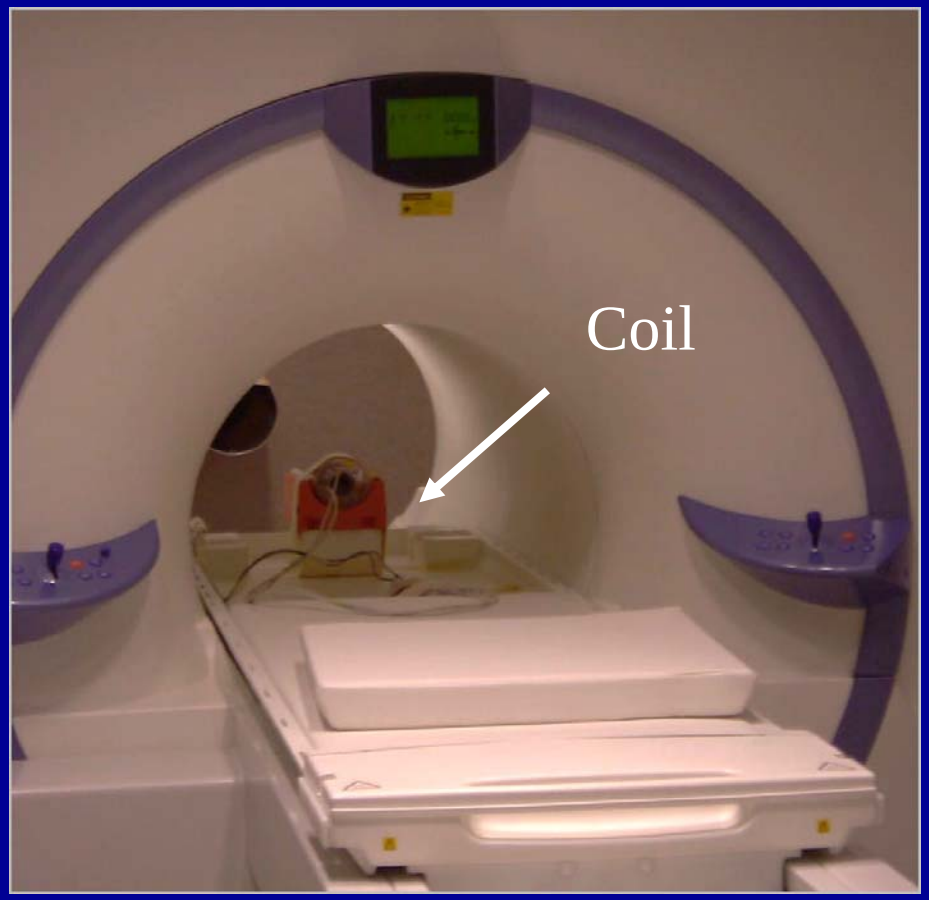

Siemens Magnetom Trio 3T scanner

OHSU Advanced Imaging Research Center (AIRC), Dr. Charlie Springer.

Iron Oxide MR Contrast Agents

SuperParamagnetic Iron Oxide (SPIO) and
Ultrasmall Superparamagnetic Iron Oxide (USPIO)

Trade name	Chemical name	Characteristics
Feridex	Ferumoxides	incomplete dextran coat, SPIO
Combidex	Ferumoxtran-10	complete dextran coat, USPIO
---	Ferumoxytol	modified carbohydrate, USPIO
-- MION --		-- preclinical preparation --

Ferumoxtran-10 and ferumoxytol were obtained from Advanced Magnetics Inc (Cambridge MA). Clinical trials were done under a Physician's IND. We have no financial interests in Advanced Magnetics Inc.

Nanoparticle MR Agents Structure



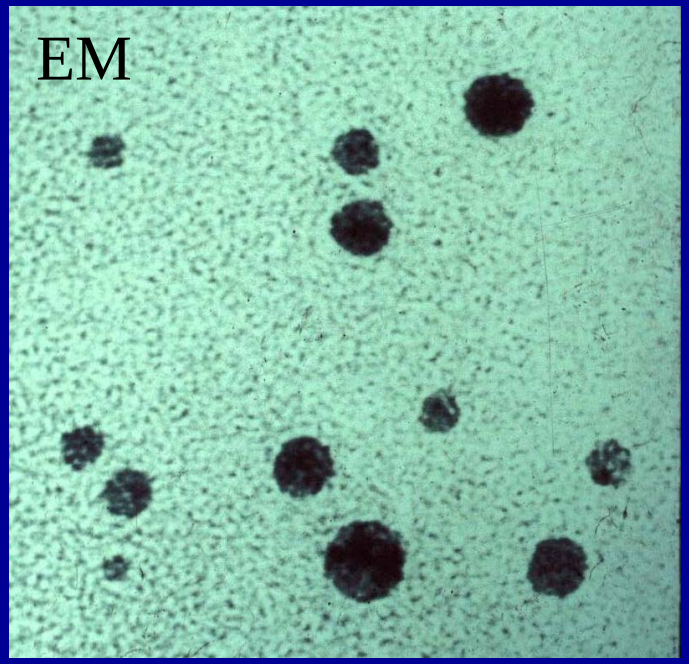

Iron oxide core coated with dextran or other carbohydrate.

Nanoparticle Localizaton in Rat Brain

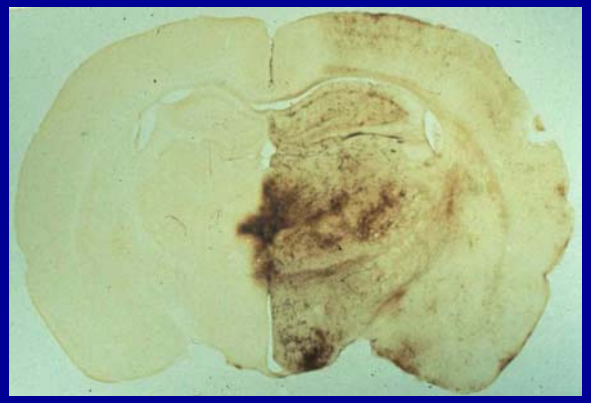

Iron oxide nanoparticles can be imaged *in vivo* by MR, and by iron histochemistry and electron microscopy in tissue sections.

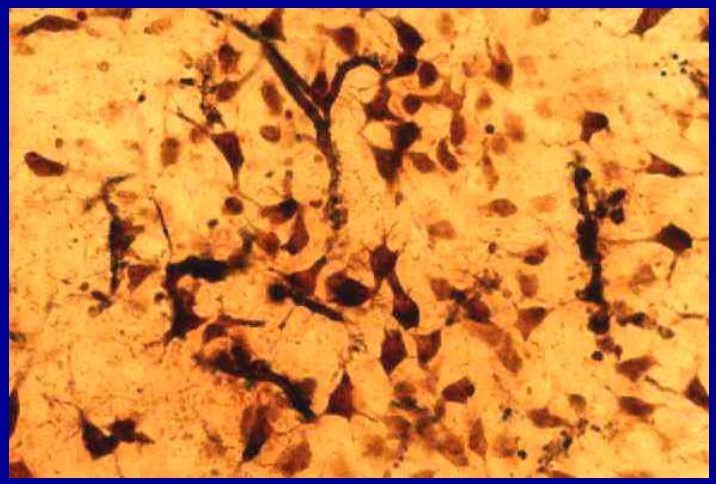

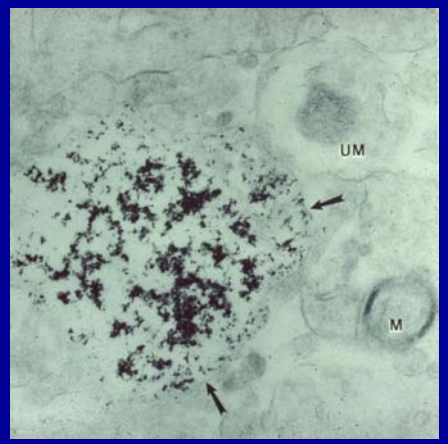

Imaging the CNS in Animal Models

Methods to circumvent the blood-brain barrier (BBB)

- Intracerebral injection -- convection
- Osmotic opening of the BBB

Neurological lesions

- Stroke, MS, iatrogenic vascular injury

Intracerebral tumor models

- Leaky vasculature and inflammation
- Growth rates, response to therapy

Convection-enhanced Delivery of Iron Oxide Agents

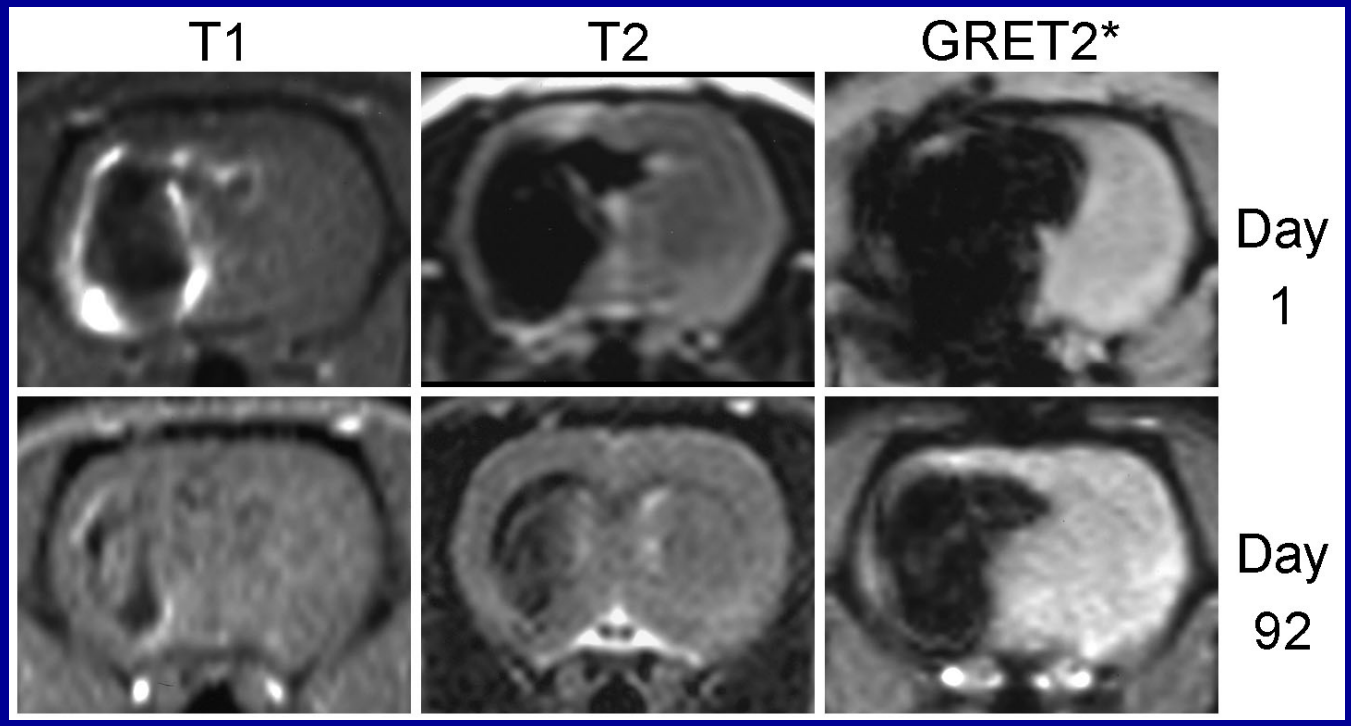

Ferumoxytol (25 µg) CED injection in rat brain

T1 and T2 signal approximate the histological iron volume, while GRET2* scans show increased apparent volume of iron due to the magnetic susceptibility artifact or blooming.

Histochemistry and Pathology

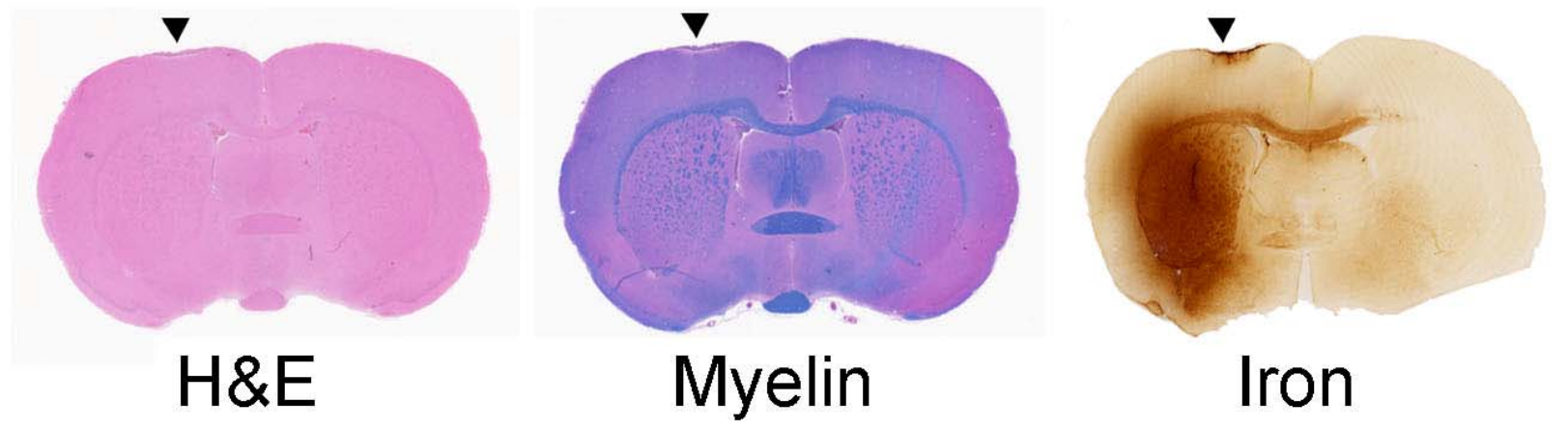

No gross pathology was noted 3 months after injection of ferumoxtran-10, ferumoxytol, or ferumoxides, except for trauma at the burr hole and needle injection site on the surface of the cortex.

No pathology was noted on H&E or myelin stains, even directly around the needle tract 3 months after injection.

Delivery of Particles to Rat Brain: Osmotic Opening of the BBB

A concentrated solution of a non-metabolized sugar (mannitol) is infused into the carotid artery for 30 seconds, displacing the blood in the brain circulation.

The capillary endothelial cells shrink, opening up the tight junction connections between cells.

The BBB is “open” for 15-90 minutes, letting agents pass from the blood into the brain.

Used clinically for brain tumor chemotherapy

BBBD Delivery of Nanoparticles

Ferumoxytol or ferumoxtran-10 (T1 MR)

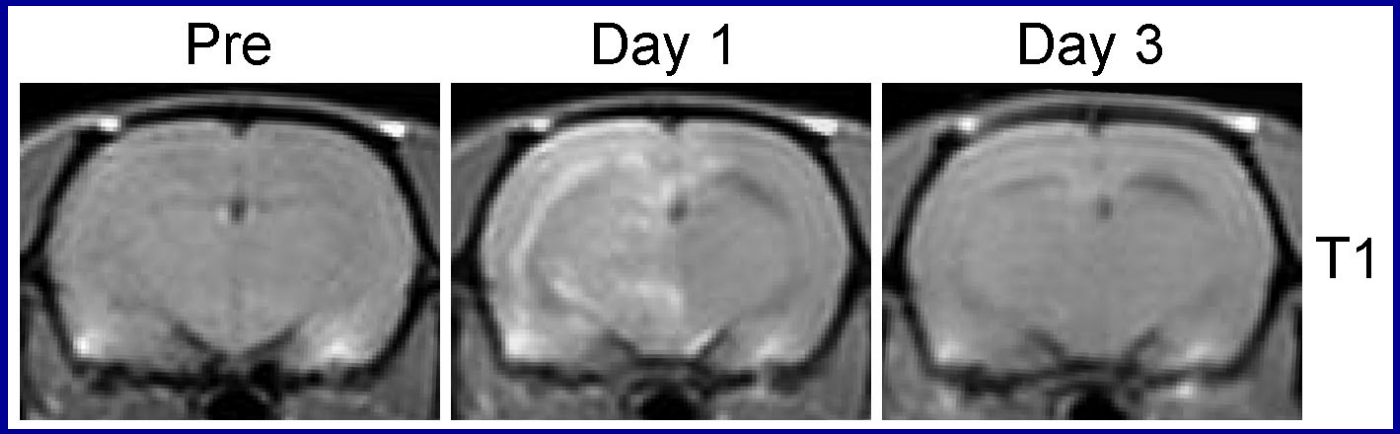

Ferumoxides GRET2* MR

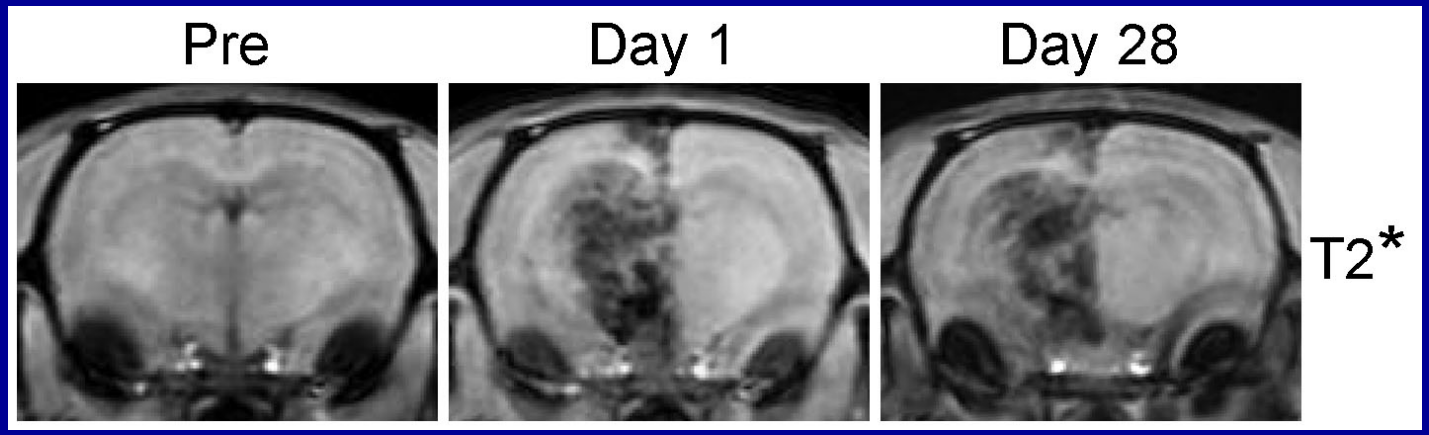

BBBD Delivery of Nanoparticles

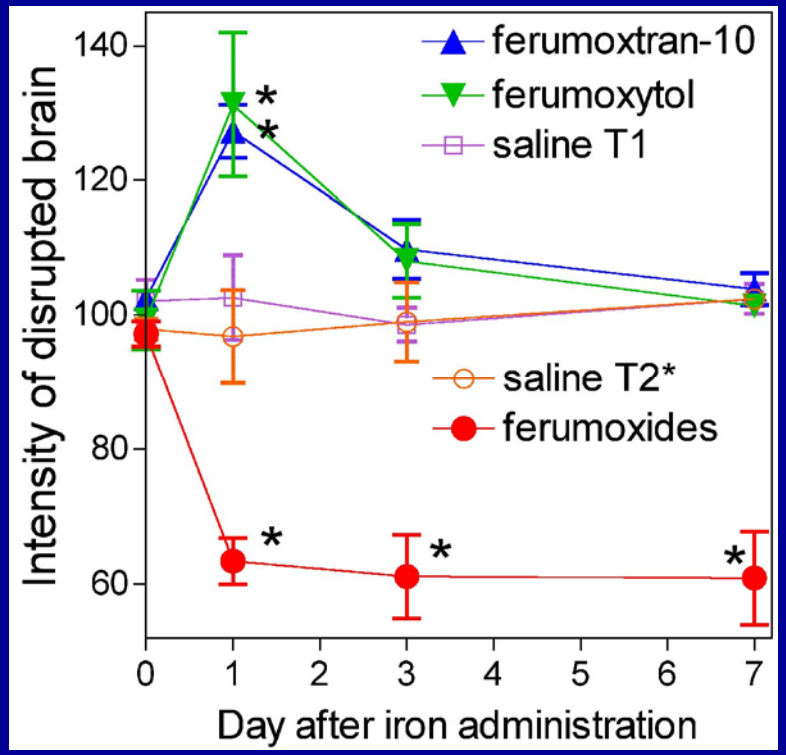

The saline control animals (BBBD without iron) showed no change in enhancement on T1 or GRET2* MR scans.

BBBD delivery of ferumoxtran-10 and ferumoxytol resulted in increased T1 signal which was significantly different from baseline at 24 h ($P < 0.02$), remained visibly detectable at 3 days, and returned to baseline within 7 days.

Imaging Neurological Lesions

Middle cerebral artery occlusion in the rat

- Temporary: 30-120 min
- Reperfusion of anoxic tissue
- Ischemic injury visible on MR by ~6h

Can the ischemic injury be visualized with the iron oxide nanoparticle imaging agents?

- Early vs. late opening of the BBB
- Small vs. large molecules
- Inflammation

Rat Model of Stroke

Temporary middle cerebral artery occlusion

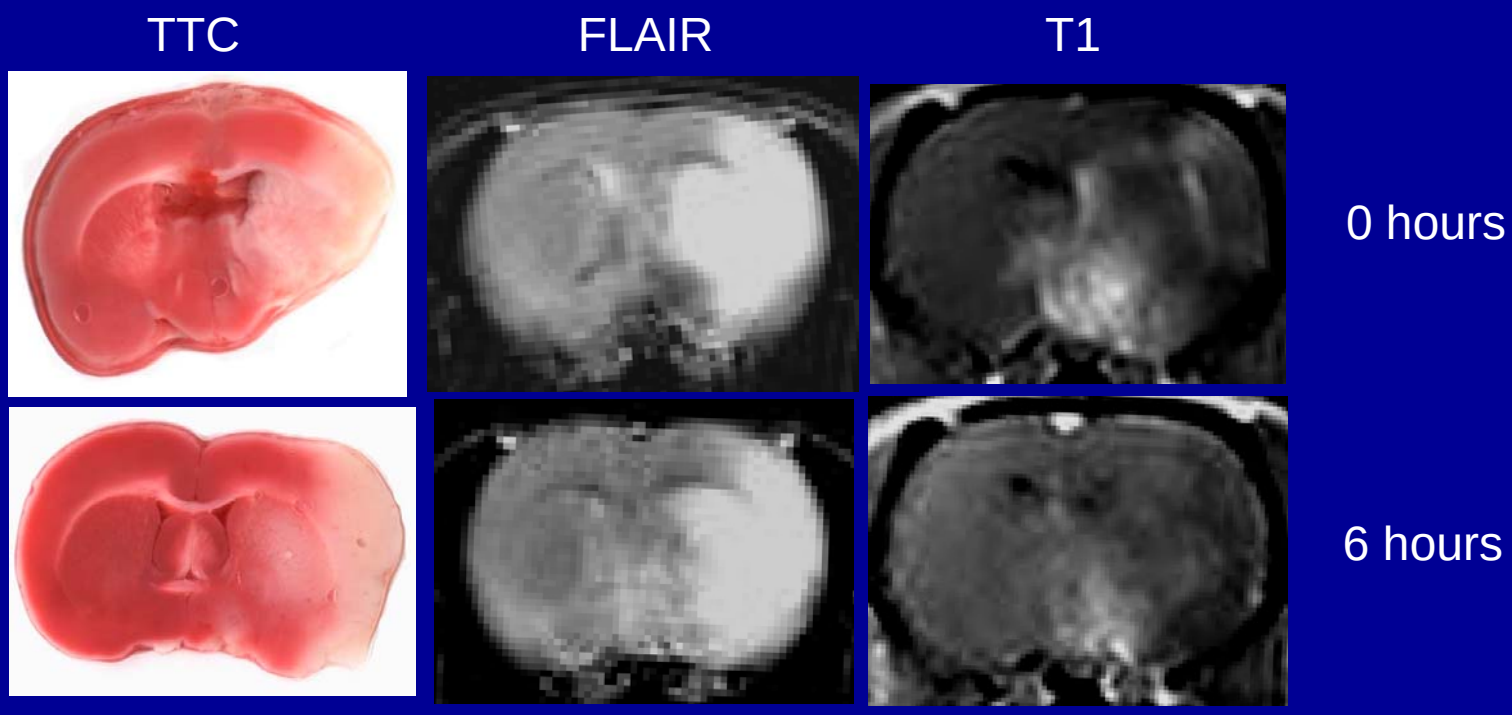

Ferumoxtran-10 was given to rats either immediately after stroke or 6 h after stroke. Rats were MR imaged 24 h after stroke

Rat Model of Stroke

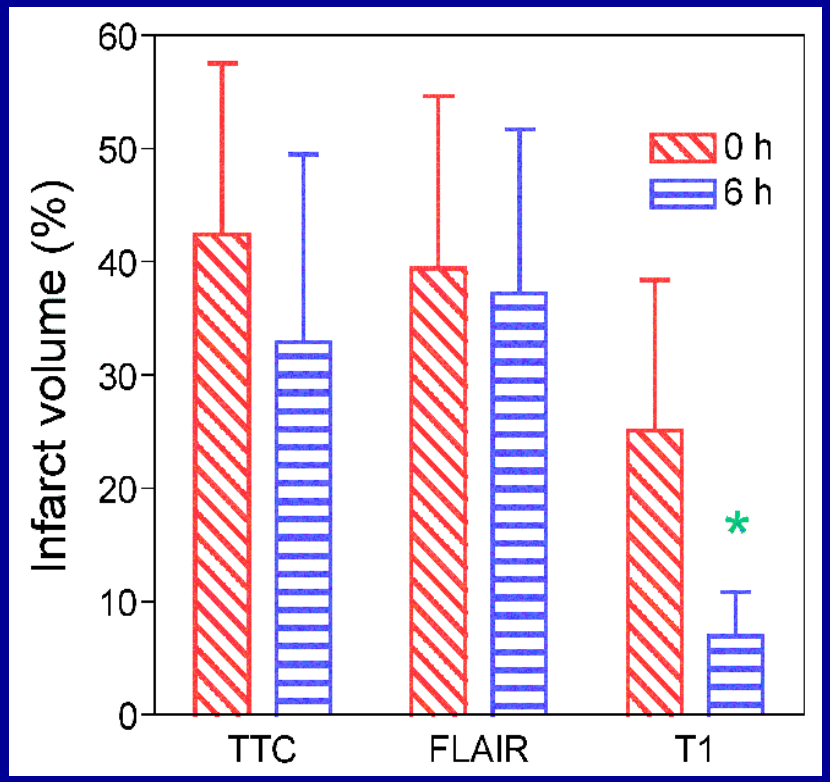

Stroke volume, as determined by TTC histochemistry and FLAIR MR, was not affected by the timing of ferumoxtran-10.

T1 MR showed enhancement in the infarcted hemisphere if ferumoxtran-10 was given immediately post reperfusion, but not if ferumoxtran-10 administration was delayed 6 h.

Brain Tumor Models

9 day

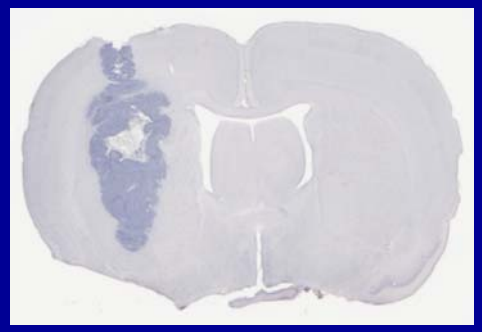

LX-1 human small cell lung carcinoma
- 15 day survival after implantation
- Necrotic areas and core
  - Similar: CALU6 SCLC

23 day

U87 human glioblastoma
- ~24 day survival after implantation
- Solid tumor

30 day

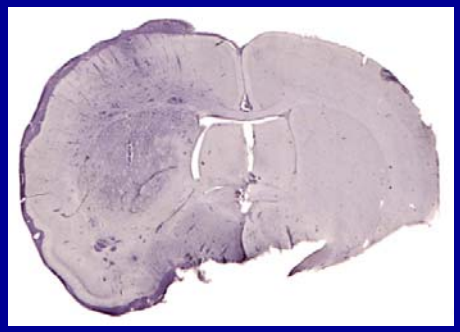

MC116 human B lymphoma
- ~30 day survival after implantation
- Diffuse tumor

Nanoparticles in LX-1 Tumors

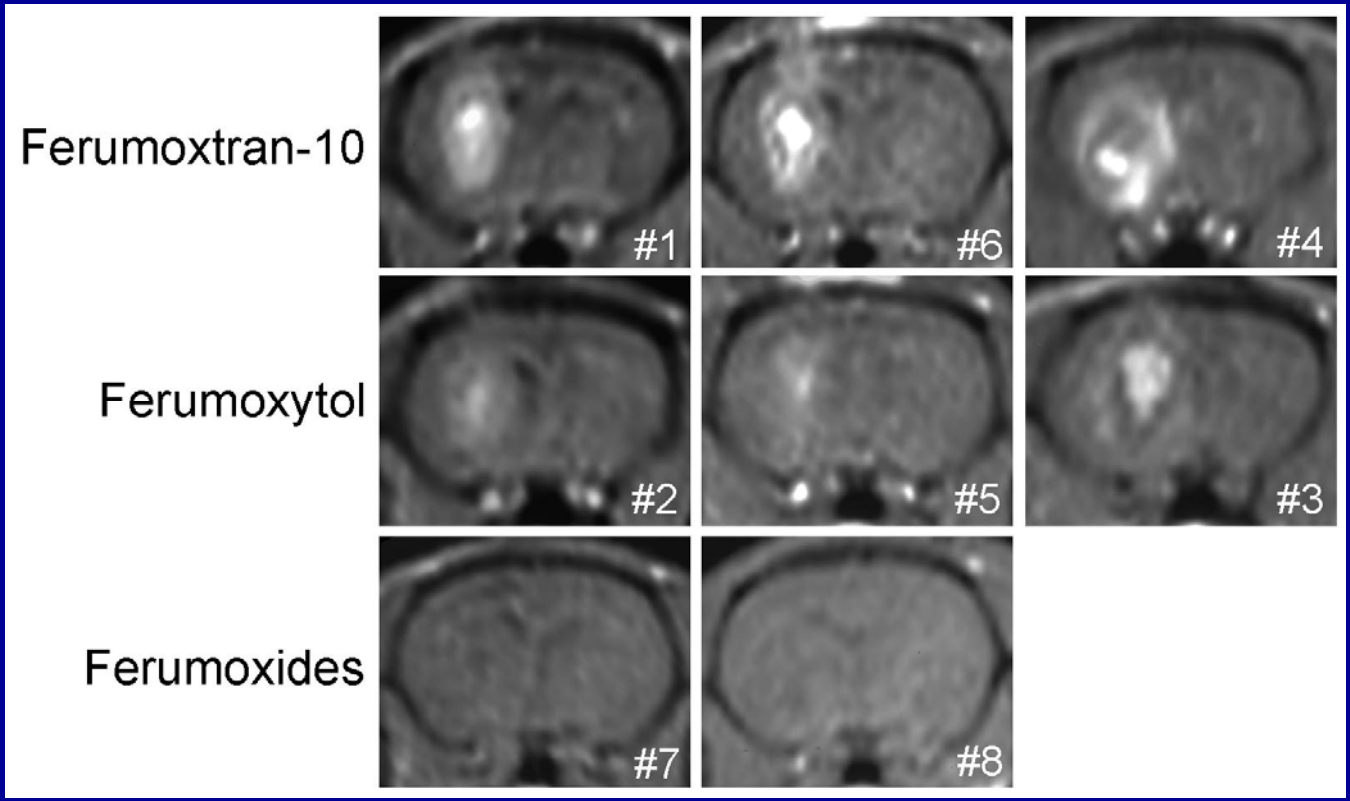

T1 scans 24 h after IV infusion of ferumoxytol or ferumoxtran-10 showed tumor enhancement. Ferumoxides did not enhance LX-1 tumors.

USPIO in Rat Brain Tumors

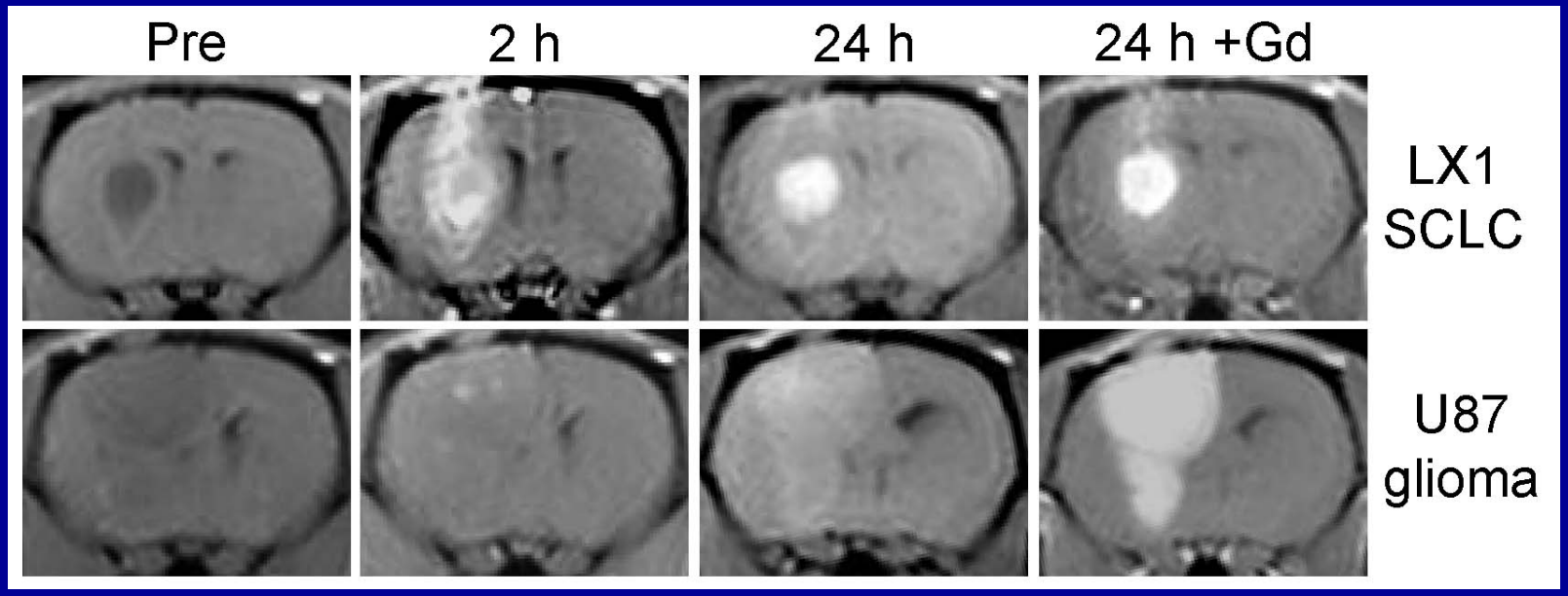

LX-1 SCLC shows high permeability and enhances with ferumoxtran-10 within 30 minutes.

U87 Glioblastoma model shows little iron enhancement even 24 h after ferumoxtran-10

USPIO in Rat Brain Tumors

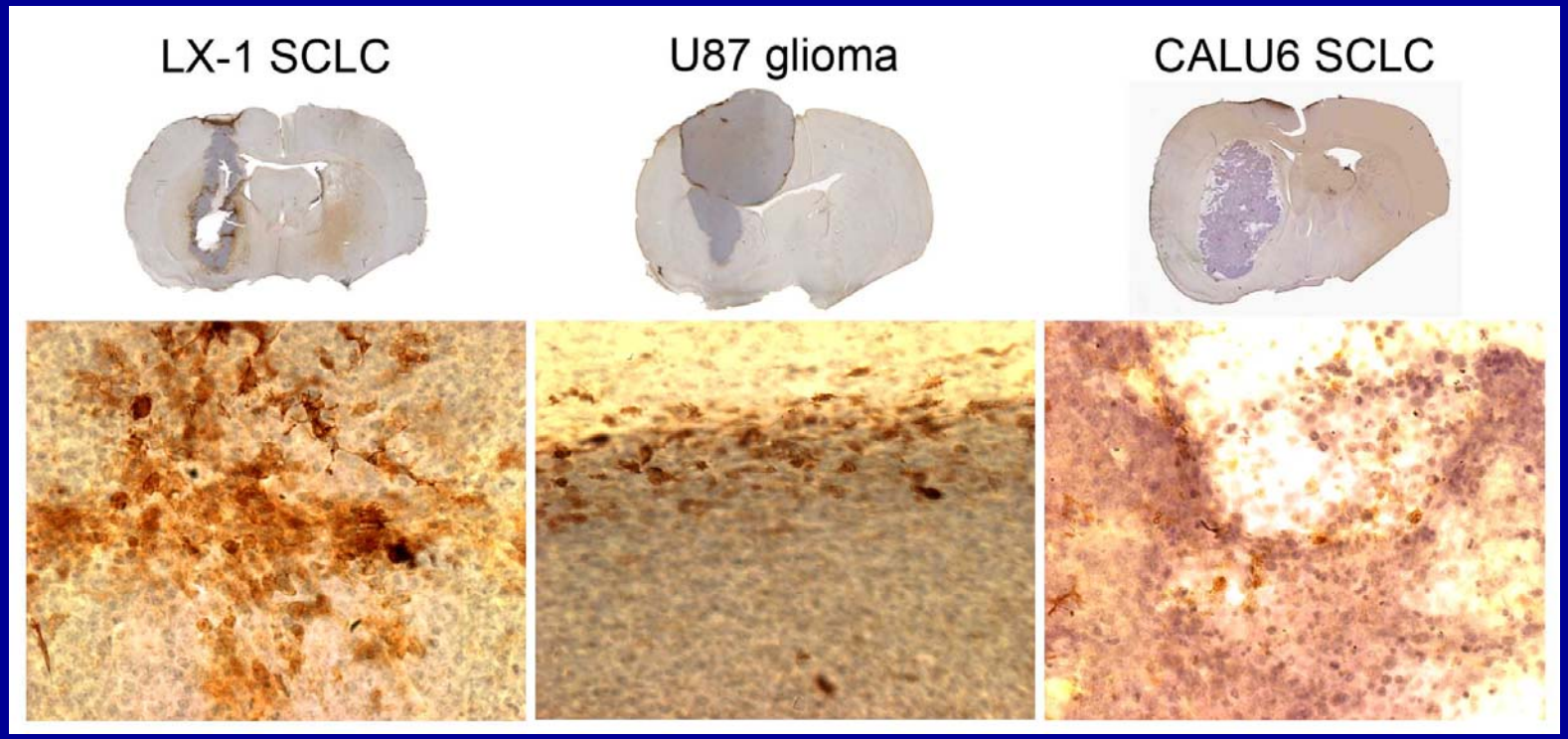

LX-1: Iron in necrotic areas and tumor margin.

U87: Iron in a band at the tumor margin.

CALU6: scattered positive cells in areas of necrosis.

MR of Iron-Loaded Tumor

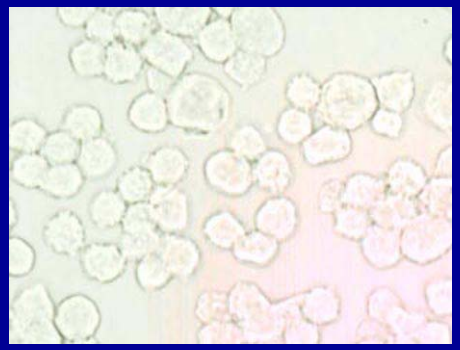

LX-1 cells

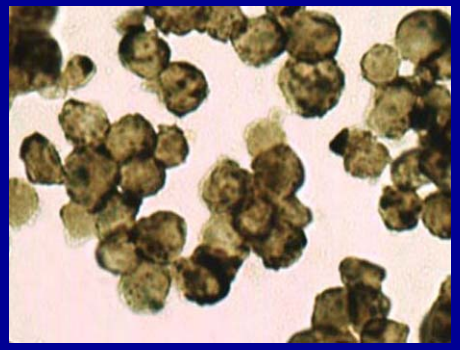

+Feridex/protamine

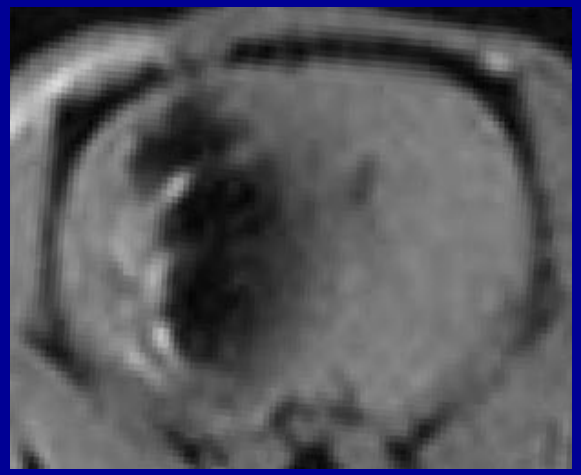

T1 MR, 13 days

Nanoparticles can be loaded into tumor cells in vitro and then implanted in rat brain.
Monitor micrometastases?

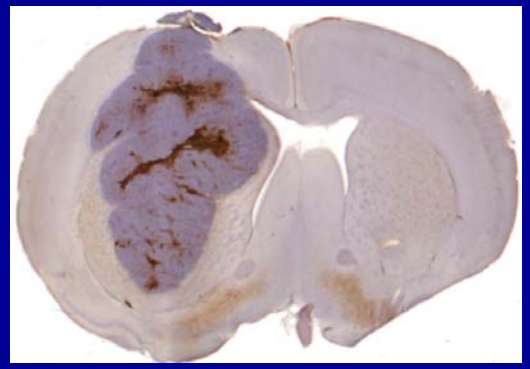

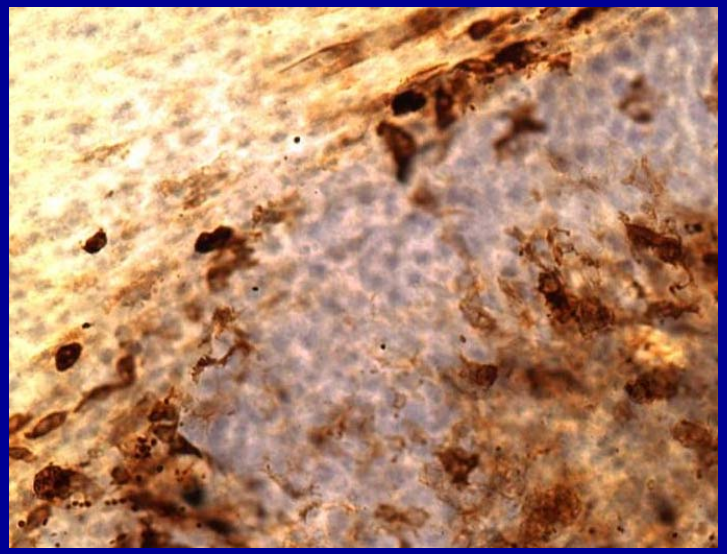

CONCLUSIONS

1. Delivery of iron oxide nanoparticle MR contrast agents to the CNS, by direct inoculation or BBBD, can be used to assess the localization, distribution, and trafficking of the particles themselves or iron-loaded cells by MR, light microscopy, and EM.

2. The iron oxide contrast agents may be useful for imaging vascular injury, neurological lesions, and CNS inflammation.

CONCLUSIONS

3. Enhancement of intracerebral tumors by the iron oxide agents is dependent on tumor type, size, and permeability.

4. USPIO and SPIO MR agents are gaining clinical use for CNS imaging. Our results demonstrate no CNS parenchymal injury with these agents, suggesting that further trials of imaging particle and stem cell trafficking in humans are warranted.

Clinical Trials with USPIO

1. Ferumoxtran-10 Imaging in Brain Tumors and Lesions

   Multi-disciplinary study: MR, histologic and EM imaging of intravenous superparamagnetic crystalline particles (Combidex) to brain, intra-cerebral tumors and in CNS Inflammation

2. Pilot Ferumoxytol Imaging in Brain Tumors

   NCI-Sponsored Multi-disciplinary study for initial timing of MR imaging of intravenous superparamagnetic crystalline particle ferumoxytol (Code 7228) in primary high-grade brain tumors and/or cerebral metastases from lung or breast cancer.

3. Ferumoxytol Imaging in Neurological and Vascular Lesions

   Multi-Disciplinary Study: MR, Histologic And EM Imaging Of Intravenous Superparamagnetic Crystalline Particles (ferumoxytol) In CNS Inflammation.

Ferumoxtran-10 (Combidex) in a GBM Patient

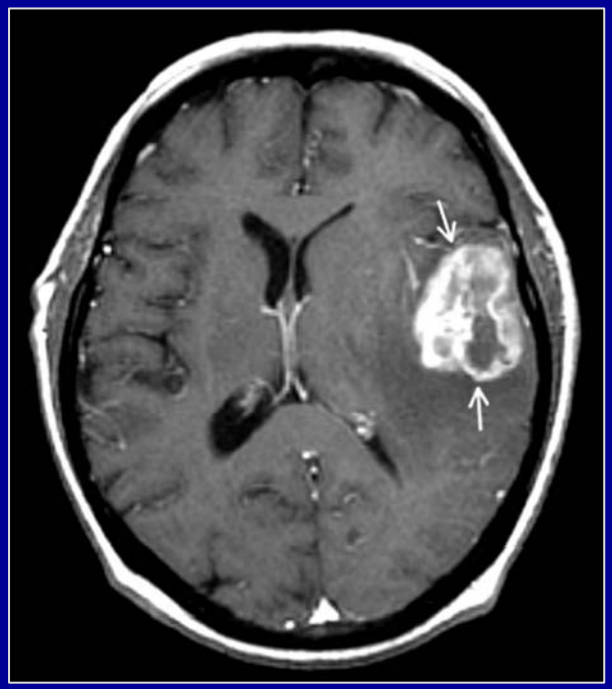

Gd

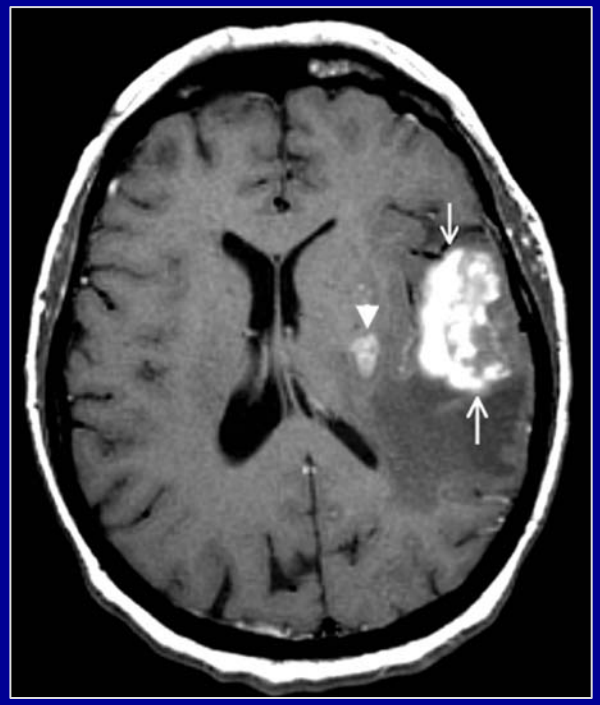

Combidex

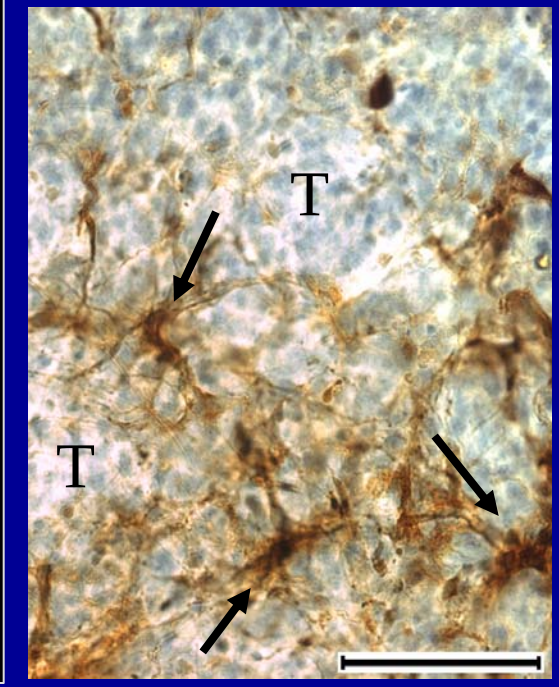

Histochemistry

OHSU Blood-Brain Barrier Program

Edward A. Neuwelt, M.D.
Nancy D. Doolittle, R.N., Ph.D.
Leslie L. Muldoon, Ph.D.

D. Thomas Dickey, DVM	Hearing studies; chemoenhancement
Y. Jeffrey Wu, Ph.D.	Iron loading; apotosis, signaling
Michael A. Pagel	Stroke model; tumor models
Sheila Taylor	In vitro studies; histology
Carole Soussain, M.D.	Neurotoxicity, Neuroprotection
Csanad Varallyay, M.D.	Animal MR studies
Matt Hunt, M. D.	Breast cancer brain mets model